

УДК 616.8

## НОВЫЙ МЕТОД ИЗУЧЕНИЯ ВОЗРАСТНЫХ ИЗМЕНЕНИЙ ПОЗВОНОЧНИКА С ПОМОЩЬЮ ЗАТЫЛОЧНОЙ ВЕРТИКАЛИ

Орел А.М.

*Московский научно-практический центр медицинской реабилитации, восстановительной и спортивной медицины Департамента здравоохранения города Москвы*

### A NEW METHOD FOR STUDYING AGE-RELATED CHANGES IN THE SPINE USING THE OCCIPITAL VERTICAL

Orel A.M.

*Moscow center for research and practice in medical rehabilitation, restorative and sports medicine of Moscow healthcare department*

#### Аннотация

Одномоментное рентгенологическое исследование всех отделов позвоночника выполнено 80 пациентам: в возрасте 60-75 лет - 37 человек, 76-88 лет - 21 и в контрольной группе в возрасте 22 лет - 45 лет у 22 человек. На экране персонального компьютера формируется единое рентгеновское изображение всех отделов позвоночника. Опускали затылочную вертикаль от точки внешнего затылочного горба и оценивали пространственное положение всех отделов позвоночника относительно этой вертикали. Описаны пять типов статики позвоночника. 0-норма, нарушений статики позвоночника нет. При I степени статического нарушения затылочная вертикаль пересекает дуги грудных позвонков. На II степени затылочная вертикаль пересекает тела грудных позвонков. На III степени затылочная вертикаль проходит впереди от тел грудных позвонков. В IV степени, помимо нарушений статики любой степени, диагностируется патологическая клиновидная деформация любого позвонка или деформация тел позвонков по типу позвонков рыб. В возрасте 22-45 лет патологические изменения статики позвоночника были редкими. В возрасте 60-75 лет наиболее часто диагностировались нарушения статики позвоночника I и II степени и появлялись нарушения статики III степени. У пациентов в возрасте 76-88 лет чаще всего диагностировались нарушения статики III и IV степени. Предлагается использовать полученные данные в качестве критериев оценки старения позвоночника.

**Ключевые слова:** Позвоночник, затылочная вертикаль, нарушения статики позвоночника, пациенты пожилого и старческого возраста, критерии старения позвоночника.

#### Abstract

A single-stage x-ray examination of all parts of the spine was performed in 80 patients: at the age of 60-75 years – in 37 people, 76-88 years-in 21 and in the control group at the age of 22-45 years in 22 people. A single x-ray image of all parts of the spine is formed on the screen of a personal computer. The occipital vertical was lowered from the point of the external occipital hump –inion – and the spatial position of all parts of the spine relative to this vertical was evaluated. Five types of spine statics are described. 0-norm, there are no violations of spine statics. At the first (I) grade of static disturbance, the occipital vertical crosses the arches of the thoracic vertebrae. At grade II, the occipital vertical intersects the bodies of the thoracic vertebrae. At grade III, the occipital vertical passes anteriorly from the bodies of the thoracic vertebrae. In IV grade, in addition to statics violations of any degree, is diagnosed a pathological wedge-shaped deformation of any vertebra or deformation of vertebral bodies according to the type of fish vertebrae. At the age of 22-45 years, pathological changes in the statics of the spine were rare. At the age of 60-75 years, the most frequently diagnosed disorders of spine statics of the I and II grade and appeared violations of statics of the III grade. Patients aged 76-88 years were most often diagnosed with statics disorders of the III and IV grade. It is proposed to use the obtained data as criteria for evaluating the aging of the spine.

**Keywords:** Spine, occipital vertical, violations of statics of the spine, patients of elderly and senile age, the criteria for the aging of the spine.

**Introduction**

The demographic situation around the world is now viewed as a crisis, which is caused by an increase in the number of elderly and senile people. The World Health Organization has developed a new age classification, according to which adult life periods are distinguished: young age from 18 to 44 years, average age from 45 to 59 years, elderly age from 60 to 70 years, senile age from 75 to 90 years, age of longevity from 90 years and older.

However, the passport age does not yet determine the true state of a person's health. When determining the physical capabilities of a person, doctors rely on the concept of "biological age", which is understood as a person's well-being, the state of his nervous system and the speed of metabolic processes, as well as the functional capabilities of other systems of organs and tissues [1].

The most obvious changes that occur during aging are registered as changes in posture, decrease in growth and muscle mass of a person [2]. The appearance of these signs is associated with systemic disorders of spine statics. However, only a few publications are devoted to a complete x-ray study of the entire spine [3]. Systematic x-ray studies of all parts of the spine at the same time in elderly and senile people have not yet been carried out.

The classic x-ray examination of the spine, carried out methodically correctly, is fraught with many new possibilities not disclosed. Modern systems for obtaining digital x-ray images have made a qualitative revolution in the x-ray examination of the spine. The radiation load has decreased tenfold and the safety of the study for patients has increased. The image quality has improved, and it is now possible to clearly identify and analyze the morphological features and spatial position of all vertebrae, which has created conditions for improving the holistic study of the spine.

This article describes the results of a new method of holistic spine research. During the study, a single combined image of the entire spine is formed on the screen of a personal computer monitor by connecting digital x-ray images of each department of spine. On the combined image of the entire spine, the occipital vertical is performed on the screen of the personal computer monitor, which begins from the point of the external occipital tubercle of the occipital bone. In Latin, this point is called "INION" [4]. Below, the occipital vertical runs along all the

structures of the spine. With its help, you can register the spatial position of all its departments [5].

**Purpose:** to describe the types of spinal statics disorders in elderly and senile people.  
**Tasks:** 1) perform radiography of all spine sections according to the standards of a sufficient number of patients of the main and control groups; 2) on the personal computer screen get single x-ray image of all parts of the spine; 3) on the personal computer screen from the point of the external occipital hump – INION – draw a vertical and evaluate the passage of this vertical relative to all spine sections.

**Research materials and methods**

Digital radiography of all spine sections of 80 patients in their vertical position was performed in accordance with the standards [6]. The focal length from the x-ray tube to the x-ray machine stand was 150 cm. On the screen of a personal computer monitor, digital images of the spine were connected to each other to obtain a single combined image of all the vertebrae, both in the sagittal and in the frontal projection. We achieved a complete match of the sizes and contours of the combined vertebrae. The software product used the graphical features of Word 2007, the Russian version, from the Microsoft® Office for home and school 2007 package.

Study groups (table 1): group I consisted of 37 patients aged 60 to 74 years. Group II included 21 patients aged 75-88 years. The control group consisted of patients 22 aged 22 to 45 years. The selection of patients in groups was made randomly. Radiographs of patients with severe static disorders, such as scoliosis of the III-IV degree and spondylololysis, most often caused by spondylololysis, were excluded from the study.

**Table.1**  
**Characteristics of groups of examined patients**

<i>groups</i>	<i>age (years)</i>	<i>number of patients</i>	<i>men</i>	<i>women</i>
<i>control</i>	22-45	22	10	12
<i>I</i>	60-75	37	13	24
<i>II</i>	76-88	21	6	15

**Results of research:**

It was possible to identify 5 types of spatial arrangement of vertebrae in the sagittal projection depending on the passage of the occipital vertical relative to the structures of the vertebrae of the middle thoracic region and morphological features of the spine. Were

allocated: 0 grade of violation of statics of the spine (norm); I, II, III and IV grade of violation of statics of the spine.

No violations of the statics of the spine (normal) (Fig. 1, 0 grade) it was diagnosed if the combined x-ray image of the patient's spine in the sagittal projection of the occipital vertical, starting from the INION point, remains behind the entire length, outside the x-ray images of the spine structures, touching the skin of the interscapular zone of the thoracic department, leaving the anatomical structures of the lumbar department and pelvis anteriorly.

II grade of violation of the statics of the spine – compensation – (Fig. 1, II grade), it is diagnosed if the combined x-ray image of the patient's spine in the sagittal projection of the cervical spine is shifted anteriorly. The occipital vertical, starting from the INION point, goes down, leaving all the structures of the cervical spine anteriorly from itself. Next, the occipital vertical touches x-ray images of the spinous processes CVII and TI, crosses the elements of the arches, including the articular processes of the TII-TV vertebrae, crosses the images of the bodies TVI-TVII of the thoracic vertebrae, but does not go beyond their anterior

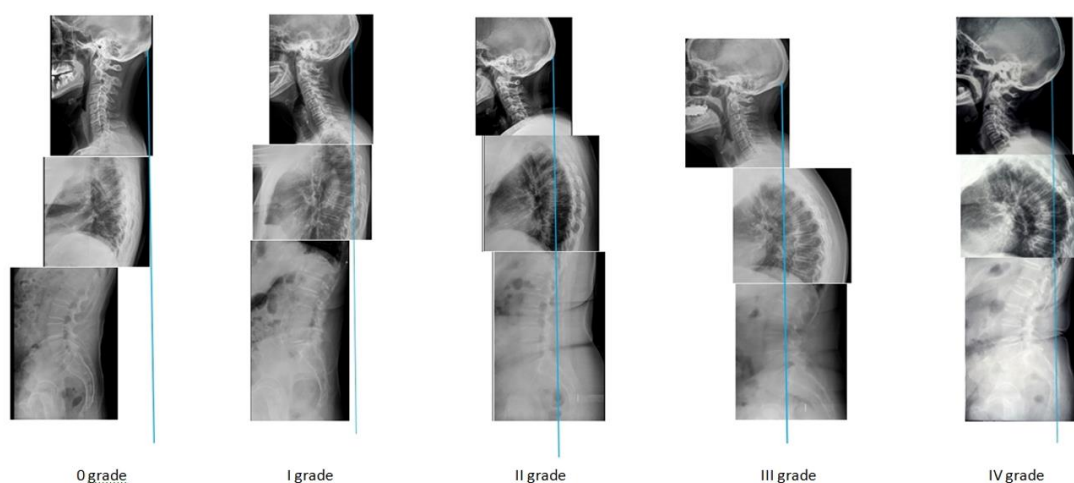


Fig. 1. The grade of violation of the statics of the spine, defined by the occipital vertical

I grade of violation of the statics of the spine (Fig. 1, I grade) it is diagnosed if the combined x-ray image of the patient's spine in the sagittal projection of the cervical spine is displaced anteriorly, the cervical lordosis is straightened or strengthened. The occipital vertical, starting from the INION, goes down, leaving all the cervical vertebrae in front of it. Below the back occipital vertical line crosses the x-ray images the spinous processes of T1–TIII of the vertebrae, crosses the images of posterior parts of ribs, spinous and articular processes, and other elements of the temples of the middle part of the thoracic spine, but does not intersect the back contours of the vertebral bodies. Below the back occipital vertical intersects x-ray images of the spinous processes of the TX and TX vertebrae, leaving all the lumbar vertebrae and the sacrum with the coccyx in front of it, crossing the soft tissues of the gluteal region.

contours and below it crosses the elements of the arches and articular processes TIX–TXII. Continuing below, the occipital vertical intersects x-ray images of the spinous processes LI–LV, intersects x-ray images of SII and the upper coccygeal vertebrae, leaving behind x-ray images of the lower sacral vertebrae, the top of the sacrum and the upper vertebrae of the coccyx.

III grade of violation of the statics of the spine – subcompensation – (Fig. 1, III grade), it is diagnosed if the combined x-ray image of the patient's spine in the sagittal projection reduces the overall size of the spine, the cervical spine is significantly shifted anteriorly, and the area of the cervical-thoracic junction rises up. In comparison with the norm, the vertebrae that make up the cervical-thoracic transition move forward and tilt down. The occipital vertical intersects the spinous processes of CVI, CVII vertebrae's. Next, the occipital vertical passes in front of the posterior

lower point of the body of the T11 vertebra, intersects x-ray images of the upper thoracic vertebrae bodies, and goes at the front from the bodies of the middle TIV-TVII thoracic vertebrae. Below occipital vertical intersects x-ray images of the bodies of the lower thoracic vertebrae TVIII-TXI, articular processes TXII, spinous processes LI-LIII. While continuing the inferior occipital vertical intersects x-ray images of the bodies of the lower lumbar vertebrae, the lower dorsal angle of the body SII of the sacrum or leaves them behind.

It is noteworthy that the prevailing number of patients in the control group had normal occipital vertical passage, and there were no violations of the statics of the spine of the III and IV degrees. In group I patients, the most common statics disorders were grade I and II. In comparison with the control group, the normal position of the spine relative to the occipital vertical was much less common. Patients with grade III spinal statics violations were identified. In group II, the III grade of spinal statics disorders was most common,

Table.2

The number of patients with disorders of the statics of the spine depending on age

groups	number of patients				
	normal (0 grade)	I grade	II grade.	III grade	IV grade
control	17	2	3		
I	6	14	12	5	
II	4	3	3	6	5

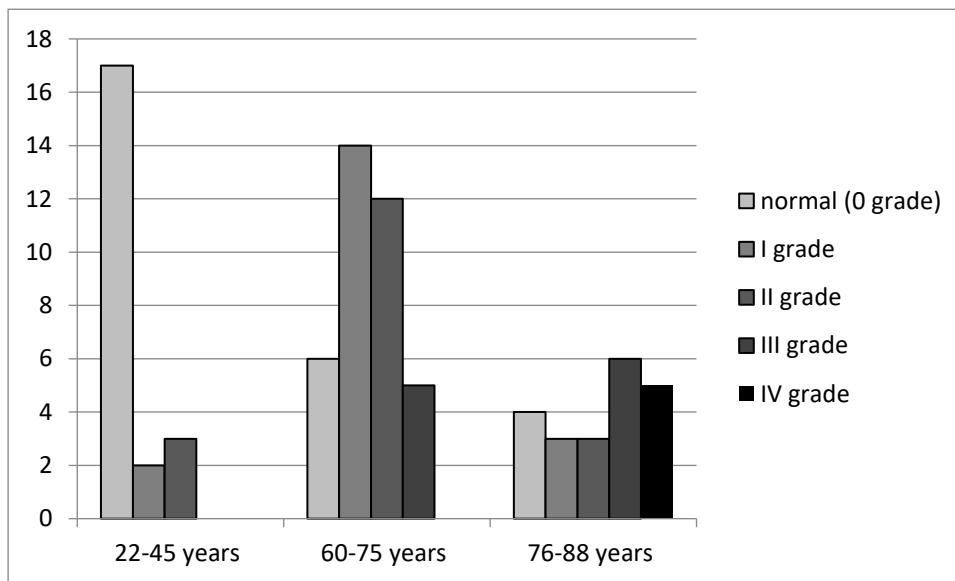


Fig. 2. The distribution of patients depending on the violations of the statics of the spine revealed by the use of occipital vertical in patients of elderly and senile age and in the control group

IV grade of violation of the statics of the spine – decompensation – (Fig. 1, IV grade), it is diagnosed when combined x-ray image of the patient's spine in the sagittal projection are signs of violations of the statics of the spine I, II, or III level, but unlike them in any part of the spine are diagnosed with a pathological fracture in the front wedge-shaped deformation of the vertebrae or multiple fractures of vertebral bodies or vertebral bodies take the form of "fish vertebrae".

The results of the study are presented in table 2 and in figure 2.

and patients with the IV grade of statics were identified. In addition, in this group, patients with I and II grade of spinal statics disorders were identified, patients with no statics violations were identified too.

**Conclusions**

A complete study of all parts of the spine at the same time using the occipital vertical opens up new opportunities for evaluating the statics of the spine. As a result of the study, it was found that depending on the passage of the occipital vertical, five types of spinal statics disorders can be distinguished.

Considering that violations of the statics of the spine of the I and II grade in young people, from 22 to 45 years, are rare, but most often occur in elderly people from 60 to 74, it is proposed to consider these signs as objective criteria for the aging of the spine. The ap-

pearance of the III, and even more so of the IV grade of spinal statics violation, the General decrease in the vertical size of the spine, which is typical for people over 75 years of age, is proposed to be used as objective criteria for pronounced aging of the spine.

### Список литературы

1. Age classification of World Health Organization [Electronic resource]. – Access mode: <https://healthperfect.ru/vozrastnye-kategorii-lyudey.html> Age classification of World Health Organization free. – The title. from the screen (date accessed: 18.01.2020)

2. Novoselov V. M. Why we are getting old. Scientific knowledge about how our body ages, why it happens and what modern ways to slow down this process / V. M. Novoselov. - Moscow: Eksmo, 2019. 272 s

3. Orel A. M. System analysis of radiographs of the spine in the practice of manual medicine/ A.M.Orel. - Moscow: Vidar-M Publishing house, 2018. – 432 p., II.

4. Fenish X. Pocket Atlas of human anatomy based on International nomenclature/ with the participation of V. Dauber; TRANS. from English. S. L. Kabak, V. V. Rudenok; Per ed. -4th ed, stereotype/ X. Fenish. - Minsk.: Higher school, 2001 - 464 p.: II.

5. Orel A.M., "A method for estimating the statics of the spine" Application for the Patent of Russian Federation № 2019144992, Priority of 30.12.2019

6. Orel A.M. X-ray diagnostics of the spine for chiropractors. Volume I: System analysis of spine radiographs. Radiological diagnosis of malformations of the spine/ A. M. Orel. - Moscow: Vidar-M Publishing house, 2006. – 312 p., II.

Поступила в редакцию 23.03.2020

### Сведения об авторе:

**Орел Александр Михайлович** – доктор медицинских наук, профессор, ГБУЗ «Московский научно-практический центр медицинской реабилитации, восстановительной и спортивной медицины департамента здравоохранения г. Москвы». e-mail: [aorel@rambler.ru](mailto:aorel@rambler.ru).

Научно-практический журнал "**Bulletin of the International Scientific Surgical Association**"  
**ISSN 1818-0698 (Print), ISSN 2078-8053 (Online)**  
 является сетевым средством массовой информации  
 по вопросам публикации в Журнале обращайтесь по адресу [surgeryserver@gmail.com](mailto:surgeryserver@gmail.com)

## Call for Papers

ISSN 1818-0698 (Print), ISSN 2078-8053 (Online)

# Bulletin of the International Scientific Surgical Association

### About Us

- Open Access
- Free Indexing Service
- Peer-reviewed
- Free Promotion Service
- Rapid Publication
- More Citations
- Lifetime Hosting
- Search Engine Friendly

### Dear Colleagues,

You are cordially invited to submit or recommend articles to ***Bulletin of the International Scientific Surgical Association*** (BISSA) which is an international academic journal devoted to the publication of original contributions in relevant areas.

The Bulletin of the International Scientific Surgical Association ISSN 1818-0698 (Print), ISSN 2078-8053 (Online) aims at quick publication of original research in all branches of surgery.

The journal is published in Russian and English.

Interested in submitting to this journal? We recommend that you review the [About the Journal](#) page for the journal's section policies, as well as the [Author Guidelines](#). Articles submitted to the editors by e-mail [surgeryserver@gmail.com](mailto:surgeryserver@gmail.com).

Copyright © 2006-2018 International Scientific Surgical Association. All rights reserved.